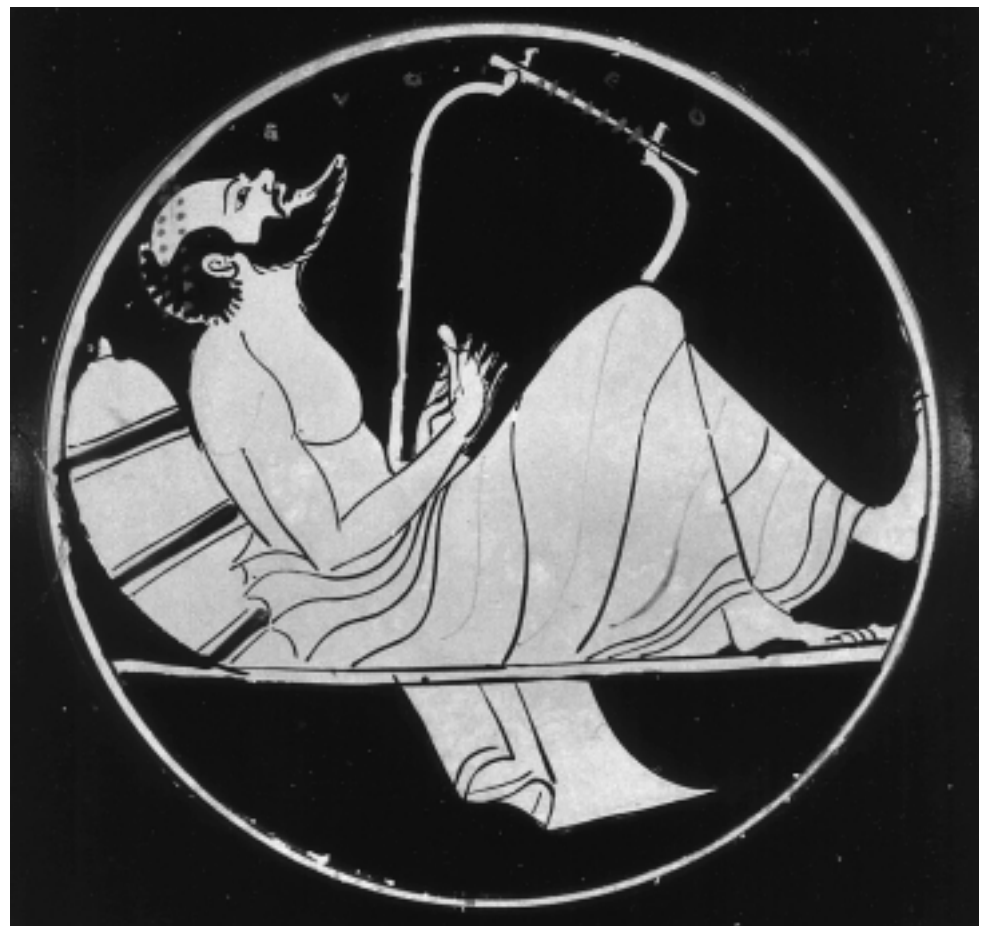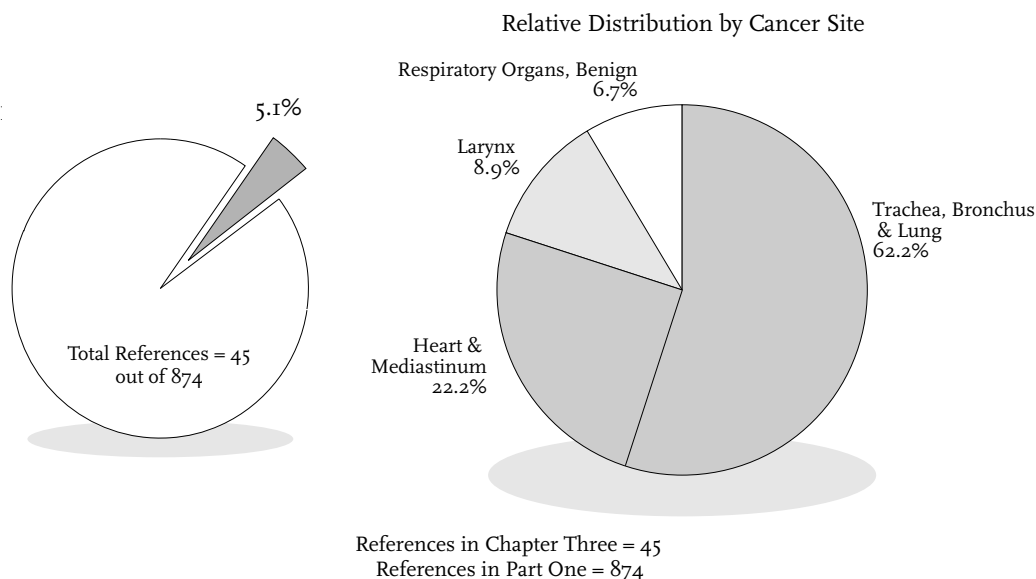


3. Remission of Neoplasms of Respiratory and Intrathoracic Organs



Remission of Neoplasms of Respiratory and Intrathoracic Organs



Cancers of the lungs, bronchii and larynx account for 16.2% of the cases of cancer reported by participating tumor registries to the SEER (Surveillance, Epidemiology, and End Results) Program between 1983 and 1987. Incidence data show that lung and bronchial cancers comprise 15% and laryngeal cancers 1.2% of the cases reported. Sixty-five percent of the cases of cancer of the lung and bronchus occurred in males as did 81.4% of laryngeal cancers. For all cases reported in males, 19.5% are lung and bronchial cancers, for females, 10.5%. Survival data (1974-1986) show that on average 11.7% of males survive five years after diagnosis and 16% of the females survive the same time period for all histologies. For oat cell and small cell carcinoma, 3.3% of the males and 6.7% of the females survive five years after diagnosis. For other histological types, 12.7% of the males and 18.3% of the females survive five years. The relative five-year survival rate for laryngeal cancer is approximately 67% for males and 64% for females. Mortality data show that cancers of the lung and bronchus account for 25.2% of the mortality cases reported to the SEER Program between 1983 and 1987 for males and females combined; 33.5% for males only, and 15.5% for females only (Cancer Statistics Review 1973-1987, published by the National Cancer Institute).

This chapter contains 45 references, 32 of which refer to malignant neoplasms and 13 to benign neoplasms. Of

the 13 reports of benign neoplasms 10 refer to cardiac tumors. Fifteen references are annotated with summaries. Some annotated references also contain 1 or more case reports. Thirty supplemental references are included to provide additional research materials. The full text of 12 case reports is presented.

A summary of the chapter contents is presented in Table One, and a comparative analysis of cases reported in previous reviews is presented in Table Two.

Table One: References and Case Reports in Chapter Three†

Tumor Site	References (number)	Cases (number)	Cases (%)
Lung (malignant)	28	8	3.1%
Lung (benign)	3	1	0.4%
Larynx	4	0	0.0%
Cardiovascular	10	3	1.2%
Totals	45	12	4.7%

† Total number of case reports in Part One is 258.

Table Two: Comparison Between Other Major Literature Reviews of Cases of Spontaneous Regression of Neoplasms of Respiratory and Intrathoracic Organs

Tumor Site	Rohdenburg (1918) (N=185)	Fauvet (1960) (N=192)	Boyd (1966) (N=97)	Everson (1966) (N=182)	Challis (1990) (N=505)
Lung (malignant)	0	1	4	2	25
Lung (benign)	0	0	0	0	1
Larynx	0	1	1	1	4
Cardiovascular	0	0	0	0	1
Totals	0	2	5	3	31

Malignant Neoplasms of Trachea, Bronchus, and Lung

A Case of Spontaneous Regression of an Untreated Bronchiogenic Carcinoma

BLADES B; McCORKLE RG

Journal of Thoracic and Cardiovascular Surgery 27: 1954; 415-419

Extracted Summary

No explanation has been found for the regression of this lung cancer. The postoperative temperature elevations were not high and cannot be regarded as significant. Drugs used by the patient are not considered important and, as far as it is known, have no carcinolytic properties.

This case represents the only known instance of spontaneous regression of a bronchiogenic carcinoma. Despite evidence of metastasis to the skull, the patient remains in good health more than five years after the original diagnosis of bronchiogenic carcinoma.

SELECTED CASE REPORT

A 59-year-old white man was admitted to The George Washington University Hospital on May 19, 1947. The patient had been in good health until September 1946, when he first noted an increase in a chronic cough which he had had for years. In addition, he gave a history of malaise and increasing dyspnea of two months' duration and an eighteen-pound weight loss over a period of six months.

The past history revealed that the patient suffered from chronic bronchitis of about twenty years' duration. He had smoked from two to three packages of cigarettes daily for many years. He gave a history of liberal alcoholic intake for about twenty-five years.

Physical examination revealed decreased breath sounds over both lung bases, particularly marked in the anterior right chest. No rales were heard. A left direct indirect hernia was present.

Roentgenograms of the chest revealed an opacity in the right lung field at the level of the third and fourth intercostal spaces anteriorly. Laboratory data demonstrated a slight leukocytosis and a moderate anemia. Further analyses were negative. Examination with the bronchoscope failed to reveal abnormal tissue for biopsy examinations. A Papanicolaou stain of the bronchial secretions was not done.

The patient left the hospital but was readmitted on July 16, 1947. Appearance of the lesion on chest roentgenograms had not changed during the eight-week period. However, there was a temperature elevation to 38.5°C. Forty-eight hours later, the temperature was normal.

On July 20, a right thoracotomy was performed which revealed a carcinoma of the lung with involvement of the right hilum and invasion of the mediastinum at the level

of the inferior pulmonary artery. A biopsy of the mass was taken and since the lesion appeared inoperable, the chest was closed. Microscopic examination of the tissue revealed an epidermoid carcinoma.

Mitotic figures were present in all microscopic fields and there could be no question about the malignancy of the lesion. The postoperative course was uneventful. The temperature remained elevated from 38 to 38.5°C. for the first three postoperative days and then returned to normal. The patient received 300,000 units of penicillin daily for five days. He was discharged on the ninth postoperative day.

During the postoperative period, roentgenograms of the chest revealed progressive clearing of the pulmonary lesion in the right lung. This became particularly apparent about six months after the exploratory thoracotomy. His general condition remained good.

The incredible behavior of the pulmonary lesion naturally aroused suspicion that there had been a mistake made in the histologic diagnosis and perhaps a mislabeled specimen accounted for an erroneous diagnosis. Accordingly, new sections were made which again revealed epidermoid carcinoma, and a careful check on the operative schedule for one week before and one week after the exploratory thoracotomy had been performed established that it was impossible for the specimen to have been misplaced since no other case of bronchiogenic carcinoma had been operated upon during that period. Moreover, subsequent developments, notably bone metastases, appeared to establish that the original lesion was malignant.

The patient was readmitted to the hospital on May 19, 1952, exactly five years after the original admission.

A careful re-evaluation of his entire life history was undertaken in an effort to obtain any pertinent facts which might have influenced the behavior of the lung cancer. Nothing of significance could be found, except that for four or five years he had been employed as a linotype operator with exposure to noxious fumes. This ultimately led him to change his occupation. Following the operation, in 1947, he took two halibut liver oil capsules daily for a considerable period of time, four vegetable compound tablets daily, an occasional barbiturate for sleep, and vitamin B₁ tablets. The vegetable compound tablets were analyzed and were found to contain asparagus, parsley, water cress, and broccoli.

Physical examination, five years after the lung cancer had been detected, revealed a thin white man, who appeared younger than the stated age of 64 years. No physical abnormalities could be detected, other than the left indirect hernia. Laboratory studies included blood urea determination, nonprotein nitrogen, acid phosphatase, and alkaline phosphatase, all of which were within normal limits. The total proteins were 5.75 gm% with an albumin-globulin ration of 1.56, albumin 3.5 gm% and globulin 2.25 gm%. Blood cholesterol was 238 mg% and cholesterol esters 48%. The blood sugar was 78% and serum amylase

40%. Multiple agglutinations were negative. Liver function studies were within normal limits. Eosinophil determination was 122/mm³ before ACTH and 56/mm³ after ACTH. An electrocardiogram was within normal limits. Ketosteroid excretion was: 1,180 cc (4.4mg/ 24 hours); 2,820 cc (10.7 mg/ 24 hours); 880 cc (7.9 mg/ 24 hours). The normal value for a man of the patient's age is from 5 to 15 mg/24 hours.

Roentgenograms of the chest, skull, pelvis, spine and femurs were obtained. Significant changes were found on the roentgenograms of the chest. There was a 3 centimeter irregular density in the left second interspace anteriorly, which had not been present on previous chest films. The almost complete disappearance of the original lesion in the right lung was constant, corresponding to roentgenograms of the past four years. In the lateral view of the skull a destructive lesion could be demonstrated in the occipital bones. The remainder of the survey of the bones revealed no metastatic lesions. The patient was discharged from the hospital after these procedures and was seen again on December 10, 1952. Roentgenogram of the chest at that time revealed no change from the x-ray obtained in May 1952.

Spontaneous Regression of Bronchogenic Carcinoma with Five-Year Survival

BELL JW; JESSEPH JE; LEIGHTON RS

Journal of Thoracic and Cardiovascular Surgery 48(6): Dec 1964; 984-990

Extracted Summary

A case history of spontaneous regression of bronchogenic carcinoma for a 5-year period is presented. The patient, a middle-aged male, with the lesion (grade 3, epidermoid) proved inoperable at thoracotomy, showed complete radiologic disappearance of this lesion in the following 6 months. The only factors of possible influence were 2 weeks of postoperative fever coincident with a noncancerocidal amount of irradiation of 1,200 roentgens. This is the first recorded case of complete regression of bronchogenic carcinoma that we can locate in the literature.

Of the many factors thought to be partially responsible for instances of tumor regressions reported in the literature, only two, fever and x-radiation, are pertinent in this case. Our patient developed a fever of 100°F. on the fifth postoperative day which persisted for one week and reached 102°F. at one point. After 2 days of normal temperature there was a sudden rise to a high of 103.2° and 102°F. the next day. Penicillin was started at this point and subsequently he became afebrile. The only clinical explanation for this was a possible transient pneumonitis without any specific organism in the sputum culture. In retrospect, the patient believed that he had had intermittent fever and occasional chills for the first month or two after returning home.

The second factor of possible therapeutic importance is the effect of radiation. Currently recommended dosage for the average patient with cancer of the lung varies from 4,000 to 6,500 roentgens. Irradiation in the range of 1,200 roentgens is believed by radiotherapists to be an inadequate or noncancerocidal tumor dose. The patient showed essentially no change in the chest lesion while on x-ray therapy. The remarkable clearing of the film occurred sometime in the 6 month interval following discharge. It should be noted that irradiation was given to this patient while he was febrile. Whether or not the fever and radiation were synergistic in effecting an immune response remains to be determined.

SELECTED CASE REPORT

A 37-year-old white man, J. M., was admitted to the Seattle Veterans Administration Hospital on February 27, 1959. He complained of exertional dyspnea for the previous 6 months which had progressed rapidly in the month before admission and was associated with left subscapular pain.

History revealed he had consulted his local physician for a chill 3 weeks prior to hospitalization. A diagnosis of pleural effusion secondary to possible pneumonia had been made at that time. The patient had been treated for chronic duodenal ulcer subsequently which had required gastric surgery 3 years before the present illness. Since the latter operation he had had no gastrointestinal complaints and was able to perform his daily work. The patient had smoked one to one and one-half packs of cigarettes daily since the age of 17 (30 pack years).

Physical examination revealed a well-developed middle-aged male. Other than dullness and decreased breath sounds in the left upper and mid-lung fields, the examination was within normal limits. Laboratory data revealed a hematocrit of 41 and white blood count of 23,600 which subsequently decreased to 10,200. Serologic tests were negative. Alkaline phosphatase was 6.3 units. Multiple sputum cultures revealed normal flora. The plasma protein electrophoretic pattern was normal. Urine and blood cultures were negative. The patient's blood type was A-Rh negative.

The admission chest film was interpreted as showing large tumor masses distributed peripherally in the left upper thorax associated with pleural effusion.

Hospital Course: Pathological examination of the left scalene fat pad revealed only hyperplastic lymph nodes. Three sputum studies were negative for malignant cells. Preoperative thoracentesis on three occasions yielded 1,600, 2,300, and 700 milliliters of serosanguineous fluid which was sterile as well as negative for malignant cells.

Bronchoscopy revealed extrinsic compression and deviation of the left main stem bronchus but no intrinsic lesion was seen.

At left thoracotomy performed on March 11, 1959, the pleural space was found to be extensively involved with tumor implants, which varied from 1 to 3 centimeters in diameter, on both the visceral and parietal surfaces. These areas of tumor growth were firm, grayish white, and homogeneous on cut section. There was pleural symphysis over most of the upper and part of the lower lobes in addition to perhaps 700 milliliters of fluid. The major fissure was separated and the tumor extended to the aortic arch from medially and above. A biopsy was taken from tumor in this area. The bulk of the upper lobe was firmly consolidated but it appeared the most likely tumor origin was from the apical-posterior segments. It was impossible to visualize the hilar structures without extensive dissec-

tion and the procedure was terminated after the frozen section diagnosis was reported as malignant neoplasm, probably epidermoid carcinoma.

Pathological Report: The microscopic sections revealed a malignant tumor in which the cells were dispersed in nests and sheets of cells with large vesicular nuclei having prominent nucleoli and a moderate amount of cytoplasm. The cells did not show individual cell keratinization, nor were keratin pearls formed. Intercellular bridges were not seen. A moderate amount of desmoplastic reaction was noted and there were small areas of necrosis. The pathological diagnosis was epidermoid carcinoma, grade 3. In this position, the pathologists believed it represented an extension of carcinoma, primary in the lung.

Tissue blocks were forwarded to the Armed Forces Institute of Pathology for review. The following report was made: Biopsy of mass from left visceral pleura, carcinoma, primary site undetermined, consistent with bronchogenic carcinoma, large cell type.

Following thoracotomy the patient complained of considerable pain in the left upper chest. Because of this discomfort, radiation was begun to the upper half of the posterior left chest on March 13, 1959, and 2,100 roentgens measured in air were given to a field measuring 15 x 18 centimeters over a period of 13 days. On March 26, 1959, an anterior portal 14 x 14 centimeters in the same area was started and 1,500 roentgens in air was given in 6 days. Technical factors included 250 kilovolts, target skin distance 50 centimeters, 1.0 mm Cu and 1.0 mm Al filter. With the use of conventional depth-dose tables without allowance for air content because of tumor and pleural fluid, a minimum depth dose of 1,200 roentgens was calculated to the midplane of the thorax. Further therapy was not given because the symptoms improved and the patient was anxious to return home. There was no response as judged by serial chest films.

Course Following Discharge: While at home the patient, who was fully aware of his disease and anticipated prognosis, states he learned that many patients who die of cancer literally starve to death. He subsequently developed a positive attitude toward survival and literally forced himself at every opportunity. He volunteered to do manual labor on a farm to be in the outdoors. During the subsequent 2 to 3 months he slowly gained weight and developed increasing strength and well-being.

The patient's first return visit for evaluation was 5 1/2 months after discharge. A chest film made at this time revealed essentially complete clearing of the tumor opacities present upon discharge. This amazing change in the x-ray study was correlated with a weight gain of 40 pounds and the complete absence of chest complaints. Thereafter he was followed at 6 month intervals and when last seen April 7, 1964, was in excellent health.

Spontaneous Regression of Bronchogenic Carcinoma

Twelve-Year Survival

EMERSON GL; EMERSON MS; SHERWOOD CE; TERRY R
Journal of Thoracic and Cardiovascular Surgery 55(2): Feb 1968; 225-230

Extracted Summary

This report describes a man whose highly anaplastic epidermoid bronchogenic carcinoma, proved by biopsy at thoracotomy, vanished completely without surgical resection, irradiation, or any other treatment. He ultimately died, 12 years later, of still another primary neoplasm. Autopsy showed no residual lung cancer.

This would appear to be unique in that there was initial pathologic proof of lung cancer and autopsy verification of its complete disappearance with no therapy.

SELECTED CASE REPORT

A 63-year-old, white, married, male printer was admitted to Strong Memorial Hospital on June 24, 1953, because of "a spot on my lung." He had been well until March 10, 1953, at which time he developed a cold characterized by running nose, sore throat, hoarseness, fever, mild chills, and a cough productive of small amounts of thick white mucus. He was treated at home supportively and returned to work in 2 weeks. A few days later he noted loss of pep, easy fatigability, malaise, and anorexia. These symptoms gradually increased over the next 6 weeks during which time there was a 10 pound weight loss. Toward the latter part of this period, there was a diminution of cough. He was then seen by a physician who diagnosed the condition as acute bronchitis; after 2 days of treatment with penicillin and aureomycin, he began to feel better. A mini-chest x-ray was taken which was reportedly abnormal and he was referred to the hospital for work-up. By the date of admission he had returned to relatively normal health, with abatement of most of the above symptoms, and he "felt foolish" about going to the hospital.

Generally his health had been good. He remembered having had measles during childhood and had been hospitalized for 2 months 35 years prior to admission for pneumonia of the right lung and had been informed then that he had a paralyzed diaphragm. He recalled having had a streptococcus infection of the throat 30 years before the present illness. Sixteen years before admission, a steel bar had bruised his right foot. Two years later, the right great toe had become swollen, painful, and inflamed. A diagnosis of gout was made and he had been treated with pills but, later, x-ray films showed "absence of bone" in a portion of the big toe. The following year, the same sequence of events involved the second right toe and, still a year later, the right ankle had become painful, swollen, and inflamed. A biopsy had been performed which "didn't show anything." Shortly after this procedure, the symptoms subsided and did not return, although the ankle had been stiff since then. He had a period of "anemia" at this

time which cleared following a course of injections. In December of 1952, he developed "indigestion" which was relieved by food and antacids. X-ray study revealed a duodenal ulcer. With treatment, symptoms were controlled.

His mother had died in her eighties of "old age." His father had died at the age of 50 years of what the family described as lung cancer. One brother and eight sisters were living and well. Two brothers died, one in World War I, the other of unknown cause. Two children were living and well.

The patient was born in England in 1889 and had completed the sixth grade. Emigrating to the United States in 1909, he had worked for 2 years on a farm. Since then, he had worked in the printing industry. Although he used neither alcohol nor drugs, he had smoked 1/2 package of cigarettes daily for many years.

Physical examination revealed a well-nourished white male, appearing younger than his stated age, in no obvious distress but with an occasional cough productive of small amounts of white mucoid sputum. The thorax was symmetrical with good and equal expansion and with a few loud crackles at both bases posteriorly. There was no dullness. Examination of the heart and abdomen revealed no abnormalities. There was ankylosis of the right ankle with an old surgical scar.

The hemoglobin was 14 gm/100 ml, the hematocrit 45%, and the corrected sedimentation rate was 41 mm/hour (Wintrobe-Lansberg) The white cell count was 8,900, with 64% segmented neutrophils, 17% lymphocytes, 8% monocytes, 4% eosinophils, and 1% basophils. There was moderate anisocytosis and slight hypochromia with normal platelets. Examination of the urine and stool showed no abnormalities. The blood urea nitrogen was 13 mg/100 ml and proteins 7.4 gm/100 ml (albumin 5.0 gm, and globulin 2.4 gm)/100 ml. Chlorides were 108 mEq/l and the prothrombin time was 100%. Fluoroscopy and multiple views of the chest revealed a right hilar nodular mass; the right diaphragm seemed to be moder-

ately elevated with restricted motion. A metastatic survey revealed no pertinent abnormality.

With the clinical impression of bronchogenic carcinoma, a bronchoscopy was performed with no positive findings. No tumor cells were identified in the bronchial washings. Acid-fast bacilli were not recovered from guinea pig inoculation or sputum cultures.

On July 2, 1953, a right exploratory thoracotomy was done which revealed no free fluid or adhesions. The peripheral lung was unremarkable. Within the hilum was a mass 6 centimeters in diameter which surrounded the right upper lobe bronchus. There was extension of this tissue around the pulmonary artery and involvement of the superior vena cava. Biopsies were taken from nodes along the superior vena cava. Frozen sections showed very anaplastic epidermoid carcinoma. On the basis of gross and microscopic findings the tumor was deemed unresectable.

Permanent sections demonstrate highly malignant appearing epidermoid cells; many foci of cancer cells are necrotic and much of the tumor is separated from the connective tissue by conspicuous numbers of plasma cells.

The patient made an uneventful recovery. His family preferred that he not be informed of the diagnosis and, on advice of his physicians, radiation therapy was deferred until such time as symptoms might develop. He was discharged on the twelfth postoperative day.

His subsequent history included painful swelling of the right thumb and wrist in 1958 (partially controlled by 9 months of triamcinolone therapy), herpes zoster in 1961, a recurrence of peptic ulcer symptoms in 1962, that were controlled by diet, antacids, and anticholinergic drugs. His general health was excellent with no chest symptoms after the thoracotomy.

In December 1961, while contacting physicians to collect all available chest roentgenograms on proved lung cancer cases in a study of early changes, we first learned of this patient's survival, 9 years after operation. At this time, he was devoting considerable care to his wife and their home after she had become invalided by a stroke in 1960. His reluctance to leave her for more than a few hours delayed our follow-up and curtailed its extent.

Chest x-ray films of May 24, 1962, revealed no evidence of the previous hilar mass. Blood studies included uric acid 4.2 mg/100 ml., white cell count of 7,600, hemoglobin of 15.3 gm/100 ml, hematocrit of 45%. No abnormal cells were seen in the buffy coat. Immunoglobulins were as follows: IgG, 1460 mg/100 ml; IgA, 123 mg/100 ml; and IgM, 68 mg/100 ml.

In December of 1964, the patient developed mild diarrhea, anorexia, and back pain. X-ray films revealed duodenal scarring from the old ulcer and colon studies

showed diverticulosis. Increasing back pain, non-bloody but frothy diarrhea, weakness, and a 40 pound weight loss led to admission to another hospital where he was treated conservatively for chronic diverticulitis. He was re-admitted to the same hospital on September 28, 1965, because of increasing back pain, epigastric fullness, and hematemesis. An epigastric mass could be palpated down to the umbilicus. At laparotomy, a large pancreatic tumor was found to be creating gastric obstruction. Biopsy of the multiple liver and peritoneal metastatic nodules, found at operation, revealed adenocarcinoma. A bypassing gastroenterostomy was performed but the patient's condition deteriorated rapidly and he died on November 12, 1965, 45 days after admission.

The surgeon who performed the exploratory thoracotomy (G.L.E.) attended the autopsy. The lungs and trachea were examined with special care. No abnormality of the tracheobronchial mucosa could be discerned on gross inspection. There was a dense area of scarring about 2 centimeters in diameter corresponding to the cancerous area seen 12 years previously. This scar tissue was adherent to the right upper lobe bronchus, carina and superior vena cava, and adjacent structures. No compression of the caval or bronchial structures could be detected. Multiple sections of the tissues in this region failed to reveal any evidence of residual carcinoma when examined microscopically. Dense fibrous scar tissue intermixed with some lymphocytes and plasma cells was the most notable abnormality outside the walls of the bronchus and related vessels. The mucosa of the bronchi and carina was formed by normal ciliated, respiratory epithelium. Other autopsy findings of note included an adenocarcinoma of the pancreas and a distinctly different latent and well-differentiated adenocarcinoma of the prostate. In addition, there was cytologic atypia in a villous adenoma of the colon suggesting the development of still another cancer. There were multiple metastases of adenocarcinoma in the liver and several small metastatic foci of adenocarcinoma in each lung. These pulmonary metastases were clearly similar to the primary adenocarcinoma of the pancreas and were distinctly different from the original anaplastic epidermoid carcinoma of the lung.

The patient's serum obtained in 1962 was tested for antibody activity to the lung removed from the area of previous tumor at autopsy. No significant complement fixation was seen. The antinuclear antibody assay with leukocyte nuclei in immunofluorescence was negative. Latex test for anti-gammaglobulins was positive in 1:640 dilution. The anti-gammaglobulin activity is a type of antibody response which may come with chronic immunization in normal persons.

Possible Immune Factors in Spontaneous Regression of Bronchogenic Carcinoma

Ten-Year Survival in a Patient Treated with Minimal (1200R) Radiation

BELL JW

American Journal of Surgery 120: Dec 1970; 804-806

Extracted Summary

A case is reported of ten-year survival after thoracotomy for inoperable bronchogenic carcinoma. Apparent spontaneous regression has been followed by freedom from development of a new pulmonary tumor in spite of the patient's continued smoking. Immunologic factors affecting this course are suggested by the demonstration of immune lymphocytes in the patient's peripheral blood which depress the growth of tumor cells from a donor with lung cancer.

In 1964 the patient reported herein was recorded (Bell JW et al., *Journal of Thoracic and Cardiovascular Surgery* 48(6) (196), 984-990) as a five-year survivor after apparent spontaneous resolution of an extensive, poorly differentiated neoplasm of the left lung, having received minimal (1200 roentgens) radiation.

During the first two postoperative weeks two events occurred which may have influenced the subsequent course. He was given a total tumor dose of 1200 roentgens through anterior and posterior portals. He manifested fever from 100 to 103°F. during most of this period. At discharge there was no change seen on the chest film.

When seen five and a half months later, the patient had gained nearly 40 pounds, and the chest film revealed essentially complete clearing of the previous lesion. The patient has been followed up at yearly intervals thereafter, and the chest film has remained clear up to this ten-year interval.

Spontaneous Regression of Bronchogenic Carcinoma

BAKER RR

National Cancer Institute Monographs 44: 1976; 31-33

Extracted Summary

Two cases of spontaneous regression of bronchogenic carcinoma were discovered in the literature, and the pertinent findings are described. The reasons for the scarcity of spontaneous regression of bronchogenic carcinoma are discussed; no apparent reasons for spontaneous regression in these two cases could be determined.

Remission of Massive Metastasis from Undifferentiated Carcinoma of the Lung Associated with Intensive Meditation

MEARES A

American Society of Psychosomatic Dentistry and Medicine. Journal 27(2): 1980; 40-41

Extracted Summary

The therapeutic process in the present case is confused by the patient's subsequent physical treatment, but the case is reported in order to record the initial seven-months remission from this highly malignant condition in the absence of any treatment at all except intensive meditation.

SELECTED CASE REPORT

The patient aged 34 years first consulted me just two-and-a-half years ago on account of a large swelling on the left side of his neck. He stated that he had been told at a leading oncology clinic that with treatment he might have 2-3 months to live but without treatment it would be a matter of 2-3 weeks. The patient declined treatment, but continued to attend the clinic for observation. He had heard of the dramatic regression of a breast cancer following intensive meditation and he sought my help. He was breathless in ordinary conversation and troubled by persistent cough. He had a biopsy of the tumor in his neck, and the clinic reported that he had a classic Pancoast tumor of the lung (histology: anaplastic carcinoma) with recurrent laryngeal nerve involvement, a left Horner's syndrome and symptoms of C8, T1 root/plexus involvement.

Treatment by meditation was complicated by lack of any cooperation from the oncology clinic. The patient had

been drinking quite heavily and this of course would greatly reduce his chances of effective meditation. He was actually encouraged in his drinking at the clinic apparently in the belief that if he had only a very short time to live he might as well do what he liked. However, in spite of minor bouts of drinking, he mastered the meditative procedure, at first seeing me daily and then less frequently, and practicing by himself at home. After seven months the mass in his neck showed little change and his physical strength was well maintained. At this stage he was told that the tumor in his neck could press on his "wind-pipe" and so cause him to suffocate. The patient panicked at this suggestion and immediately sought physical treatment. He has had a considerable amount of radiation and the swelling in his neck has subsided. Now two and a half years after first seeing me he is still able to get about in reasonable comfort.

Spontaneous Regression of Epidermoid Carcinoma of the Bronchus

DEPIERRE A; BRETON JL; GARNIER G

Revue des Maladies Respiratoires 1(2): 1984; 113-117

Extracted Summary

A spontaneous regression of epidermoid carcinoma of the bronchus is reported here for only the third time. (Blades & McCorkle, 1954; Emerson et al., 1968) This report concerns a 57-year-old patient suffering from chronic air flow obstruction who had twice required artificial ventilation. Fiberoptic bronchoscopy was performed on account of hilar asymmetry and a small tumour on the carina of the middle lobe was discovered. The biopsy confirmed the existence of a moderately differentiated invasive epidermoid bronchial carcinoma. An examination performed four years later failed to reveal this tumour. Immunological studies showed only a notable rise in NK cells.

SELECTED CASE REPORT

The patient is a 57-year-old man with a history of heavy tobacco and liquor usage who was hospitalized in 1979 (file no. 1993) for chronic respiratory insufficiency due to obstructive bronchitis. In the past medical history of this patient, a butcher by profession, are two professional injuries (thoracic in 1966 with fracture of ribs, and a severe wound to the flexor tendons of the left hand in 1970); two visits to the emergency medical clinic for artificial resuscitation from delirium due to over-intoxication in 1970 and 1973. Upon arrival in the hospital the patient was suffering from acute hyperventilation accompanied by purulent expectoration; there was no recent hemoptysis, no peripheral tumoral syndromes. He was revived and maintained.

Biologically, the essential anomalies were a nonspecific inflammatory syndrome (sedimentation rate, 37/70, hyperleukocytosis with 10,700 white cells, 67% polynuclear neutrophils, fibrin 6 gm/l) and abnormalities of the liver variables (alkaline phosphatase 118 IU) probably

linked to the alcohol intoxication. The pulmonary radiography, besides the observation of chronic obstructive bronchopneumopathy and the after effects of costal fractures (right) clearly showed an increase in volume of the right hilum, without atelectasis or associated segmentary pneumopathy; there was present an indistinct opacity, irregular, left basal, along the costal margin; an image which was not found on the tomographic profile. It was already visible in 1973 and was considered to be an old pleural injury.

On March 29, 1979, a bronchoscopic examination was performed: "On the carina of the right middle lobe, on the parietal side is noticed a whitish substance, evidently tumor-like which is biopsied twice. The carina of the inferior right middle lobe is enlarged." Bronchial aspiration did not bring up any atypical cells. On the other hand the anatomic-pathologic examination of the biopsy (no. 7115-79, Prof. Ag. Pageaut, Dr. Ranfaing) showed "a fragment invaded by an epidermoid proliferation in the bronchial

lining and infiltrating the subadjacent chorion as strands in a fibrous and lymphocytic stroma. The lining was of irregular thickness and without an orderly cellular arrangement. The infiltrating strands are composed of cells with a low amount of cytoplasm, sometimes clear, without a unifying bridge and without keratinization. Occasional mitosis is also found. All of these above facts would seem to eliminate a simple epidermoid metaplasia or dysplasia."

The diagnosis was epidermoid epithelioma moderately differentiated. No metastases were found: the mediastinum was free, abdominal echography, osseous scintigraphy, and cerebral scanning did not reveal any metastases. Angiopulmonography showed normal right pulmonary arteries. The tumor was classified T₁ N₀ M₀. It should be noted that no other bronchial biopsy was performed that day. The patient refused all specific therapeutic treatment.

On February 9, 1981, 2 years after the diagnosis was made, the patient underwent radiography in a clinic; no change was noted in the right hilum. On January 19, 1983, the patient returned to the medical service for acute respiratory insufficiency accompanied by hypoxia and hyperuria, respiratory encephalopathy and rales. No tumor was found upon clinical examination. He was treated conservatively with kinesitherapy and bronchial dilators. He had lost no weight since last examined.

On standard thoracic radiography, a rather dense

vascularization of the hilum, especially on the right, was noted. The front and side tomographies do not show ganglion or tumor images. Bronchi endoscopy performed January 24, 1983, showed bronchi which were normal except for a few mucous irregularities on the external wall of the middle lobe, which were biopsied.

Bronchial aspiration produced a muco-inflammatory substance rich in alveolar macrophages, and biopsies (no. 1652-83 Pr. Ag Pageaut, Dr. Ranfaing) showed "two fragments of bronchial mucous membrane, one showing a fibrosis of the chorion; the other showing microcystic cells of the seromucous glands." All explorations to find hepatic, osseous and cerebral metastases were negative.

During those 4 years, no surgical or anti-mitotic therapy (chemotherapy, radiotherapy or immunotherapy) was performed on this patient. An immunological study was performed on this patient 4 weeks following this last hospitalization. Standard results showed no peculiarities: white cells 7,360 with 49% neutrophils and 39.5% lymphocytes; red blood cells 5,300,000 with 17 grams of hemoglobin; rate of sedimentation was 12/34; electrophoresis of proteins was normal; immunoglobulins were normal; inflammatory proteins were normal; the total complement was normal, but there was an increase of the fraction C₃: 165 (normal 50-120) and C₄: 61 (normal 20-50); there were no circulating immune complexes, no autoantibodies, no rheumatoid factor, or cryoglobulin.

(Noetic Sciences translation)

Spontaneous 19-Year Regression of Oat Cell Carcinoma with Scalene Node Metastasis

LOWY AD JR; ERICKSON ER
Cancer 58(4): Aug 15 1986; 978-980

Extracted Summary

This is the first case report of a patient with oat cell carcinoma of the lung with scalene node metastasis who, without treatment, is alive 19 years after the original diagnosis was made by biopsy. Seven years before the publication of this report, and at the age of 66 years, he underwent coronary bypass surgery and there was no gross evidence of malignancy present.

SELECTED CASE REPORT

In 1966 a 55-year-old white man, referred by his family physician, was admitted to Western Pennsylvania Hospital in Pittsburgh with a history of shortness of breath of 6-weeks' duration. He gave a history of smoking 30 cigarettes per day for years but had quit 4 months before admission. Physical examination was normal except for suspicious palpable glands in the right supraclavicular area. Chest x-ray of September 22, 1966, showed prominence along the right mediastinal border just above the hilus, which suggested node enlargement or neoplasm. There were no radiographic changes to suggest emphysema.

A right scalene node biopsy was performed surgically

under local anesthesia and a positive diagnosis was made of metastatic undifferentiated small cell carcinoma or oat cell carcinoma.

The discharge summary from the hospital record stated: "It was felt that this patient's symptoms were minimal at this time, but since he was completely inoperable and incurable, nothing would be gained by giving him treatment such as radiation therapy or nitrogen mustard. These cases are usually of a fast growing nature. He was told that he had a tumor which, if it developed symptoms, could be treated. We thought it best that he return to work as soon as possible."

He was next seen in 1971 while his family physician

was vacationing. He had an acute shoulder problem which required hospitalization. This was five years after the diagnosis of oat cell carcinoma with metastasis had been made. Routine chest x-ray was reported as negative and all prior x-rays were reviewed by the radiology department. A handwritten, signed report by a radiologist who had never seen these films before was as follows:

January, 22 1966 - Definite mass above the hilus. This extends from the level of the aorta knob (most prominent here) up to the clavicle; 3/16/67...Mass is not present ...absolutely not present. Conclusion: Inflammatory nodes unrelated to the scalene node biopsy. Was the scalene node really malignant? Suggest review by pathologist.

The microscopic slides were perused by several members of the pathology department and diagnosis remained oat cell carcinoma unanimously.

In 1973 he developed a typical angina pectoris and was treated medically. On admission to the hospital 5 years later, in 1978, his chest pain was analyzed as two types. One was typical severe coronary insufficiency, and the other was initiated by eating and most likely related to the

hiatal hernia which had been seen in 1971 on a routine upper gastrointestinal x-ray series. An angiography study of the coronary vessels a week later was followed on February 1, 1978, by an aortasaphenous vein bypass to the right coronary artery (dominant with critical significant stenosis in the mid portion) and left internal mammary artery bypass to the left anterior descending coronary artery (80% stenosis). There was no gross evidence of any malignancy and both pleural cavities had been opened during the procedure.

Because of recurring angina, another arteriography study was performed in October 1978, and both grafts were found patent. Now, however, the circumflex division of the left coronary vessel showed total proximal occlusion. Therefore, medical therapy was continued. When the patient was last seen in 1980, he was under treatment with cimetidine hydrochloride for a reflex esophagitis. In May 1984, his wife called me from Florida because they needed a referral in the Pittsburgh area. He had had pneumonia during the winter and his physician desired follow-up chest x-rays.

Spontaneous Regression of Squamous Cell Lung Carcinoma With Adrenal Metastasis

SPERDUTO P; VAEZY A; BRIDGMAN A; WILKIE L
Chest 94(4): Oct 1988; 887-889

Extracted Summary

A 61-year-old man was found to have squamous cell carcinoma of the left hilum with metastasis to the left adrenal gland documented by needle aspiration. About two years later, the primary tumor is not detectable, and the adrenal gland is of normal size on follow-up computerized tomography. To our knowledge, this is the first documented case of spontaneous regression of squamous cell carcinoma of the lung with adrenal metastasis.

"In conclusion," the author states, "Spontaneous regression of cancer seems to be a real phenomenon whose mechanism remains unknown. This area should continue to attract research, as it certainly harbors clues which may some day aid in further elucidating the mystery of cancer."

SELECTED CASE REPORT

A 61-year-old white man presented with left flank pain that was similar to his previous attacks of nephrolithiasis. A routine chest x-ray film on admission showed a left hilar mass, and the patient was referred for pulmonary evaluation. His history was significant for smoking more than one pack of cigarettes per day for all of his adult life, moderate chronic obstructive pulmonary disease with chronic productive cough, and excision of multiple basal cell skin carcinomas. In addition, the patient had a diagnosis of anxiety and depression with auditory hallucinations, for which he had been receiving amitriptyline and perphenazine daily in recent years. He denied taking any other medications or having any other new symptoms.

Physical examination revealed a well-developed well-nourished man, who was mentally clear and in no acute

distress. He had a hearing aid and was oriented and communicating well. Vital signs were normal. He was 173 centimeters tall, weighing 72.5 kilograms. Chest examination revealed some scattered expiratory rhonchi. Findings from the physical examination were otherwise unremarkable.

Laboratory evaluation included a normal complete blood cell count and serum chemistry (Chem 18). Pulmonary function tests revealed a forced vital capacity of 2.32 L (50 % of predicted) and forced expiratory volume of 1.22 L (38 %), with values after bronchodilator administration of 2.72 L and 1.45 L, respectively. While breathing room air, arterial blood gas levels were as follows: pH 7.39, arterial oxygen pressure, 63 mmHg (91 % saturation); and arterial carbon dioxide tensions, 42 mmHg.

Computerized tomography of the chest and upper

abdomen revealed a 3 centimeter mass in the posterior left hilum and a 6 centimeter left adrenal mass. Fiberoptic bronchoscopy failed to detect any intrabronchial findings. The patient underwent a left anterior thoracotomy for diagnostic biopsy. Needle biopsy (Tru cut) of the left hilar mass revealed squamous cell carcinoma. Computerized tomographically guided needle aspiration of the left adrenal gland revealed numerous malignant cells, compatible with metastatic squamous cell carcinoma. These slides were reviewed by three independent pathologists. No treatment was undertaken, and the patient was discharged in November 1985.

Since discharge the patient has remained asymptomatic and has been followed in the pulmonary clinic every three months. He stopped smoking cigarettes and has continued his previous medications (amitriptyline and perphenazine) prescribed from the psychiatry clinic. The patient did not receive any treatment for his cancer. Follow up chest x-ray films showed a gradual decrease in the size of the left hilar mass, and the last x-ray film showed a normal left hilum. Computerized tomography of the chest failed to show a left hilar mass, and computerized tomography of the upper abdomen revealed a left adrenal gland of normal size.

Spontaneous Regression of Cancer

PAPAC RJ

Connecticut Medicine 54(4): Apr 1990; 179-182

Extracted Summary

Over half of the reported cases of spontaneous regression of cancer reviewed by Everson and Cole developed in four tumor types, renal cell carcinoma, neuroblastoma, malignant melanoma, and choriocarcinoma. The circumstances and undoubtedly the mechanisms of regression differ. Clinical features of these tumor types are presented.

The author has observed eight patients (1 with adenocarcinoma of the lung, 2 with malignant melanoma, 1 with multiple myeloma, 1 with liver metastases from colon carcinoma, 1 with myelomonocytic leukemia, 2 with renal cell carcinoma) who have experienced spontaneous regression of cancer. Brief case summaries are presented.

Two additional cases considered to be spontaneous regressions, although we have not been directly involved in the management of these cases, have also been observed. One patient presented at a tumor conference had gastric carcinoma with hepatic metastases found at surgery. Without any additional therapy, the liver metastases resolved, documented by re-exploration a year later. The second patient, seen only in consultation, had chronic lymphocytic leukemia which underwent remission for a four-year period following a bout of pneumococcal pneumonia.

SELECTED CASE REPORT

Case 1: NR, a 62-year-old woman, was seen initially in 1981 for a second opinion regarding chemotherapy for carcinoma of the lung. Three months earlier she had had a left upper lobectomy for adenocarcinoma of the lung. On follow-up evaluation a bone scan was consistent with metastases to ribs and pelvis. A computed tomographic scan of the abdomen showed three focal defects. The patient and her husband decided to defer chemotherapy for several months and vacation in the

interim. In 1989 the patient returned again for a second opinion regarding chemotherapy. A year after the initial visit and without any chemotherapy or specific therapy the scans were found to be entirely normal. Following an eight-year period during which the patient was clinically free of metastatic disease, a bone scan was again abnormal and biopsy revealed metastatic adenocarcinoma, consistent with the primary lung carcinoma.

SUPPLEMENTAL REFERENCES
MALIGNANT NEOPLASMS OF TRACHEA, BRONCHUS, AND LUNG

- Considerations sur les Stabilisations Spontanées et Provoquées du Cancer, A Propos d'une Observation d'Épithélioma Pulmonaire à Cellules Claires Suivie pendant Quatre Ans
JOSSEAND A
Journal de Medecine de Lyon 36: Apr 5 1955; 273-277
- Results of the Surgical Treatment of Bronchogenic Carcinoma
SENENIG DM; ROSSI NP; EHREHAFT JL
Surgery, Gynecology and Obstetrics 116: 1963; 279-284
- Empyema Thoracis
LEROUX BT
British Journal of Surgery 52: Feb 1965; 89-99
- Spontaneous Regression of Malignant Disease: Report of Three Cases
MARGOLIS J; WEST D
American Geriatric Society. Journal 15(3): March 1967; 251-253
- Effect of Postoperative Empyema on Survival of Patients with Bronchogenic Carcinoma
TAKITA H
Journal of Thoracic and Cardiovascular Surgery 59(5): May 1970; 642-644
- Spontaneous Regression of Carcinoma of Bronchus
SUTTON M; PRATT-JOHNSON JH
Clinical Radiology 21(3): Jul 1970; 256-258
- Spontaneous Regression and Metachronous Contralateral Occurrence of Bronchial Carcinoma
GAUTAM HP
American Review of Respiratory Disease 103: 1971; 275-277
- Cure of Lung Cancer from Incomplete Surgical Resection
SMITH RA
British Medical Journal 2: June 5 1971; 563-565
- Spontaneously Regressing Cavitated Pulmonary Lesion
GELMAN MI; FREUNDLICH IM
Chest 61(7): Jun 1972; 680-681
- Anaplastic Lung Cancer with Metastases: Case Report of a 15-Year Survival
GREENTREE LB
Ohio State Medical Journal 69(11): Nov 1973; 841-843
- Spontaneous Regression of a Bronchial Carcinoid Tumor Following Pregnancy
LUOSTO R; KOIKKALAINEN K; SIPPONEN P
Annales Chirurgiae et Gynaecologiae Fenniae 63(4): 1974; 342-345
- Spontaneous Regression of a Lung Cancer Accompanied with Empyema: A Case Report
SAWAMURA K; MORI T; CHIKAMORI J; IUCHI K; NAGAOKA U; IIOKA S; MANJO S; YOKOYAMA K; FURUSE K; FUKUOKA M; MATSUDA J
Japanese Journal of Cancer Clinics (Gan No Rinsho) 21(5): 1975; 345-348
- Histological Type of Bronchial Carcinoma and Long-Term Remission Following Tissue Resection
LANGER J; RZEPECKI W; LUKASIEWICZ M; GORALCZYK J; LUKIANSKI M; HARAZDA M
Nowotwory 28(2): Apr-Jun 1978; 179-186
- The Relationship between Postoperative Empyema and Long-Term Survival After Pneumonectomy: Results of Surgical Treatment of Bronchogenic Carcinoma
LAWAETZ O; HALKIER E
Scandinavian Journal of Thoracic and Cardiovascular Surgery 14(1): 1980; 113-117
- Temporary Spontaneous Regression of Lung Cancer
POH SC; CHIANG SC
Singapore Medical Journal 25(5): 1984; 354-358
- A Case of Spontaneous Regression in Lung Cancer
KATO M; YOSHITOMO K; MASTUSHITA T; KATO J; HAYASHI Y; TUZUKI M; TASHIRO T; ITO G; TAKEUCHI T; TATEMATU M
Nippon Kyobu Shikkan Gakkai Zasshi (Japanese Journal of Thoracic Diseases) 24(2): 1986; 188-194
- Long-Term Development of a Case of Spontaneous Regression of a Bronchial Epidermoid Cancer
DEPIERRE A; BRETON JL; GARNIER G; DALPHIN JC
Revue des Maladies Respiratoires 4(2): 1987; 101-102
- Hepatocellular Carcinoma After Spontaneous Regression of Extensive Small Cell Lung Cancer
NAKANO T; TAMURA S; HIGASHINO K
American Journal of Medicine 84(1): Jan 1988; 178-179

Malignant Neoplasms of the Larynx

Carcinoma of the Larynx

A Case of Apparent Regression After Inadequate Therapy

LEVINE MI; REIDBORD HE; BUSIS SM
Archives of Otolaryngology 91: April 1970; 385-386

Extracted Summary

Regression of carcinoma of the larynx after inadequate therapy is rare. Carcinoma of the larynx was diagnosed histologically in one patient following a stripping procedure of the larynx. This was not considered adequate therapy, but further therapy was refused. There was no evidence of this tumor at laryngoscopy two years later or at autopsy 12 years after the initial tumor was found. This patient developed another unusual finding, a metachronous carcinoma of the lung, which caused his death. (Permission to reproduce case report denied by authors.)

SUPPLEMENTAL REFERENCES MALIGNANT NEOPLASMS OF THE LARYNX

Contribution a L'étude de la Guérison Spontanée de Certaines Tumeurs Maligues

BROECKAERT J

Annales des Maladies de l'Oreille, du Larynx, du Nez et du Pharynx 7: 1914; 1-13

Case of Spontaneous Regression in Laryngeal Cancer 1 1/2 Years After Unsuccessful Radiotherapy

KUBO M

Japanese Journal of Clinical Medicine (Nippon Rinsho) 26(9): Sep 1968; 2121-22

Papilloma of the Larynx: Carcinoma, Recurrence, Spontaneous Remission

BERTRAND H; DOUCET F; CORNUDET B; LEBRETON M; GARRIGUE G

Journal Francaise D'Oto-Rhino-Laryngologie 29(5): May 1980; 333-334

Benign Neoplasms of Respiratory Organs

Spontaneous Regression of Pulmonary Leiomyomas During Pregnancy

HORSTMANN JP; PIETRA GG; HARMAN JA; COLE NG JR; GRINSPAN S
Cancer 39(1): Jan 1977; 314-321

Extracted Summary

Multiple pulmonary nodular densities simulating metastatic cancer were discovered in a routine chest roentgenogram of a 30-year-old pregnant woman. Lung biopsy revealed nodules composed of smooth muscle and collagenous tissue containing entrapped glandular elements. The lesions were initially interpreted as multiple pulmonary fibroleiomyomatous hamartomas (MPFLH). During pregnancy and the postpartum period, the pulmonary nodules regressed spontaneously. A review and critical analysis of published cases as well as our own case indicates that multiple pulmonary fibroleiomyomatous hamartomas cannot be distinguished from benign metastasizing leiomyoma (BML) by either clinical, roentgenographic, or pathologic criteria and that all represent pulmonary metastases from a primary uterine neoplasm. The spontaneous regression of the pulmonary nodules in the present case as well as the increased risk for development of progressive pulmonary insufficiency in the pre-menopausal patients indicates an apparent hormonal dependence. Total abdominal hysterectomy and bilateral salpingo-oophorectomy appears to be the treatment of choice.

SELECTED CASE REPORT

A 30-year-old pregnant black woman, D. C., was admitted for the first time to the Hospital of the University of Pennsylvania on August 12, 1974, because of threatened abortion. Past medical history included acute rheumatic fever in 1952, left nephrectomy for congenital pelvoureteral stenosis in 1965, and three unremarkable pregnancies in 1964, 1965 and 1966. Pertinent physical findings were intrauterine pregnancy estimated at 14 weeks, uterine bleeding and multiple uterine leiomyomas. Following two days of bed rest, the vaginal bleeding ceased spontaneously.

As part of the medical work-up, a chest roentgenogram, which had been normal two years previously, was performed and demonstrated an extensive bilateral reticular nodular interstitial infiltrate. Skin tests for tuberculosis and fungi were all negative. Quantitative urinary human chorionic gonadotropin levels as well as B-mode ultrasound scanner were compatible with pregnancy of 15 weeks gestation. Pulmonary function studies were consistent with a moderate restrictive lung disease. Fiberoptic bronchoscopic examination and bronchial biopsy were negative. A left thoracotomy with wedge biopsy of the lingula was performed on August 21, 1974. The lung tissue contained numerous discrete, ovoid, firm, gray-white

subpleural and intraparenchymal nodules which varied in size from 1.2 millimeters to 2.7 millimeters in diameter. On histologic examination, the nodules were covered by a cuboidal epithelium and composed of interdigitating bundles and whorls of smooth muscle and collagenous tissue with entrapped glandular structures. No nuclear atypism or mitoses were seen in the mesenchymal or epithelial components. On the basis of these histological findings the lesions were classified as multiple pulmonary fibroleiomyomatous hamartomas (MPFLH). The postoperative course was unremarkable and the patient was discharged on August 27, 1974.

The remainder of her prenatal course was uncomplicated. A chest roentgenogram obtained on November 20, 1974, demonstrated a slight but definite reduction in the size and number of the nodules. On January 30, 1975, labor was induced with intravenous oxytocin because of falling estriol levels and full-term male infant was delivered vaginally. The immediate postpartum chest roentgenogram performed on February 1 revealed a significant reduction in the size and number of the nodular densities compared to the November film.

During the postpartum period she remained asymptomatic and elected to breast-feed her infant. Uterine

leiomyomas were no longer palpable on pelvic examination. Chest roentgenogram obtained on March 15, 1975, demonstrated a further reduction in size and number of the interstitial nodular densities which have remained unchanged through July 1975 (11 months after her first admission). Pulmonary function tests, performed concurrently with the chest roentgenograms, demonstrated a corresponding progressive improvement.

Collating the physical findings and clinical course with careful histologic review of the sections and literature search, it was felt that the disease process represented benign metastasizing leiomyoma (BML) rather than multiple pulmonary fibroleiomyomatous hamartomas (MPFLH). Based upon the revised diagnosis and the apparent hormonal response of the lesion, an elective total abdominal hysterectomy and bilateral salpingo-

oophorectomy was performed on July 23, 1975. The uterus measured 9.5 x 6.0 x 4.0 centimeters and weighed 147 grams. A small subserosal leiomyoma as well as numerous intramural leiomyomas measuring from 1.3 to 2.5 centimeters in greatest diameter were present. The ovaries and fallopian tubes appeared normal. Histologically, the leiomyomas were extremely cellular but without nuclear atypia or mitoses. Within the myometrium a cellular leiomyoma had disrupted the normal architecture of a large vein with destruction of the venous wall and protrusion into the lumen. Other findings consisted of proliferative endometrium, normal fallopian tubes and ovaries. The patient's postoperative course was uneventful and she was discharged to be followed in the Gynecology-Oncology and Pulmonary Clinics.

SUPPLEMENTAL REFERENCES BENIGN NEOPLASMS OF RESPIRATORY ORGANS

Benign Tumours of Larynx
CAPPS FCW

Journal of Laryngology and Otology 71: Nov 1957; 709-17

Multiple Bilateral Fibromas of the Pleura
SCATTINI CM ; ORSI A

Thorax 28(6): Nov 1973; 782-787

Neoplasms of the Heart and Mediastinum

A Report of Three Cases of Cardiac Tumors in Children with Favorable Courses

KHATTAR H; GUERIN R; FOURON JC; STANLEY P; KRATZ C; DAVIGNON A
Archives des Maladies du Coeur et des Vaisseaux 68(4): 1975; 419-429

Extracted Summary

During a 14-year period, 8 cases of primary heart tumours were observed at Sainte-Justine Hospital. Three of these patients had a favourable course without any surgical treatment. The age of these patients was respectively 3 days, 7 weeks, and 6 1/2 years. The clinical and para-clinical symptomology of the first two patients was suggestive of heart disease from the onset. Catheterization and angiocardiographies confirmed the presence of a tumour deforming both ventricular cavities. In these two cases, an attempt at surgical resection proved to be impossible in view of the extent of the lesion. Biopsy demonstrated rhabdomyoma in one of the patients and a diffuse fibroma in the other. Six and four years later, the patients were still alive, and improvements of both the electrocardiogram and of the cardiopulmonary x-ray pictures were noted. A second cardiac catheterization showed an almost complete disappearance of the pathological images. The third case regards a 6-year-old child with a classical Bourneville tuberous sclerosis with a localized tumour at the junction of the superior vena cava and the right atrium. Three years later a control catheterization showed the tumour to have remained unchanged. Two conclusions might be

drawn from these cases: 1) a surgical operation, although always indicated, should never involve a desperate attempt at tumour removal; 2) the prognosis should never be considered as lethal from the start.

SELECTED CASE REPORT

A three-day-old female, M. T. B., was admitted to the hospital in July 1965 for cyanosis and heart murmur. Physical examination showed a slight degree of respiratory distress. Auscultation revealed a systolic murmur of weak intensity graded II/IV along the left side of the sternum. Electrocardiogram showed a marked left ventricular hypertrophy with alterations of the repolarization phase. Cardiopulmonary x-rays revealed extreme cardiomegaly. Cardiac catheterization and angiocardiography revealed the presence of a very large tumor infiltrating a large part of the heart. This tumor compressed the right ventricle to the right and up while the left ventricle was displaced downward. The ascending aorta was compressed posteriorly and to the right. In addition, a right-left shunt was observed at the auricle. It was impossible to enter the ventricular cavities with the catheter.

During the operation, surgical resection proved to be impossible on account of the extent of the lesion. The heart was enormous and compressed the lung posteriorly. The tumor did not present distinct borders with the

normal myocardium. From the tumor, the pulmonary artery could be seen arising as a portion of the auricular appendix. Histology of the biopsy confirmed the presence of a rhabdomyoma.

The patient left the hospital in good condition. She was rehospitalized 6 years later for neurological symptoms: psychomotor retardation and epilepsy. A diagnosis of tuberous sclerosis was made. From the cardiac point of view, the persistence of a slight precordial systolic murmur was reported. On the other hand, the cardiopulmonary x-rays showed only a slight cardiomegaly.

At the same time, the left ventricular potentials were notably diminished as compared to the curve obtained at admission. Another cardiac catheterization with angiocardiography showed no tumoral image. The cardiac cavities were no longer displaced and had a normal morphology except for the left ventricle which appeared slightly deformed. The given hemodynamic measurements were normal. (Noetic Sciences translation)

Benign Mesenchymal Tumor of the Heart

Spontaneous Regression and Disappearance of Pulmonary Artery Stenosis

LEE Y-C; SINGLETON RT; TANG C-K

Chest 82(4): Oct 1982; 503-505

Extracted Summary

We describe a patient who was found to have a large benign mesenchymal tumor of the right ventricular wall and right pulmonary artery stenosis at the age of 20 months. Following biopsy of the tumor, the patient's respiratory distress improved gradually and cardiac catheterization at the age of ten years showed normal intracardiac pressures and disappearance of right pulmonary artery stenosis. He remained asymptomatic at age 20. Possible factors for the spontaneous regression of the tumor are discussed.

SELECTED CASE REPORT

A 20-month-old baby was admitted to the University of Maryland Hospital on fourteenth of December 1959. The prenatal history was unremarkable and the delivery was uneventful. Since the age of 14 days, he had been admitted to a local hospital on numerous occasions due to dyspnea and wheezing. He was found to have marked cardiomegaly, and treatment with digitalis failed to improve the symptoms. Physical examination on admission revealed a well-developed, well-nourished boy without cyanosis or clubbing. Blood pressure was 100/60 mmHg, and pulse rate was 150/minute with frequent premature beats. The chest was symmetric and coarse rhonchi were heard throughout. The heart was markedly enlarged; a grade 3/6 ejection systolic murmur was heard over the

base and the second heart sound at the pulmonic area was widely split. The liver was palpable 2 centimeters below the right costal margin. Hemoglobin was 10 gm/dl, white blood cell count was 11,500/ml with 65% polymorphs, 22% lymphocytes, 12% monocytes, and 1% eosinophils. Result of PPD skin test was negative. Electrocardiogram revealed sinus tachycardia with frequent ventricular premature beats and right bundle branch block. The chest x-ray film revealed marked cardiomegaly and there was a suggestion of a large mass lesion on the right side of the heart at the base.

Right heart catheterization was performed on December 21, 1959. There was no evidence of intracardiac shunt by blood oxygen analysis. The pressures (mmHg)

at the various sites were as follows: right atrium mean, 9; right ventricle, 60/5; main pulmonary artery, 60/18; left pulmonary artery, 60/18; right pulmonary artery, 25/16; and the pulmonary artery wedge mean, 13. Angiocardio-gram showed a large, soft, tissue mass arising anteriorly on the right side of the heart and compression of the right pulmonary artery. There was no filling defect of the cardiac chambers.

Exploratory thoracotomy was performed on March 10, 1960. There was a large, multinodular, whitish, rubbery mass arising from the right ventricular wall extending to the pulmonary artery which appeared inoperable. A small section of the tumor was obtained for pathologic study and the chest was closed. The postoperative course was uneventful.

The biopsy specimen consisted of fragments measuring 0.8 x 1.2 centimeters in aggregate. The tissue was whitish in color, soft and homogeneous, partly covered by a greyish glistening membrane. Microscopically, some areas were more cellular than others. The tumor was composed almost exclusively of spindle cells which possessed elongated nuclei with inconspicuous nucleoli. The cytoplasm was relatively scanty and eosinophilic. Long cytoplasmic processes were frequently observed. In the more cellular areas, the tumor cells formed bundles or fascicles, whereas in the less cellular areas, the tumor cells were arranged in a haphazard fashion and were separated by clear spaces. Masson trichrome stain demonstrated abundant extracellular collagen fibers. Cross striations were not identified by PTAH stain. No acceptable elastic fibers were found with Verhoff-von Gieson stain. There

was a rich vasculature, mainly capillaries, within the tumor tissue. This tumor is unusual as it did not conform exactly to any of the recognized soft tissue lesions. It was believed to be a benign mesenchymal tumor and most likely fibroblastic.

During the ensuing years, dyspnea and wheezing improved gradually, although digitalis was discontinued, and he did not receive any form of treatment. He was able to attend school and participate in sports activities. He was readmitted to the University Hospital on April 14, 1969 for cardiac catheterization at which time he was asymptomatic. Physical examination revealed a well-developed, well-nourished boy. The blood pressure was 120/78 mmHg, and pulse rate, 62/minute with occasional premature beats. The heart was not enlarged, no murmur was heard and the pulmonic second sound was physiologically split. The chest x-ray film showed no evidence of cardiomegaly and there was pleuropericardial scarring on the right mediastinal area. The electrocardiogram showed sinus rhythm with occasional unifocal ventricular premature beats and incomplete right bundle branch block. Cardiac catheterization revealed no evidence of intracardiac shunts; intracardiac pressures were as follows: right atrial mean, 7; right ventricle, 30/4; main pulmonary artery, 28/14; right pulmonary artery, 28/14; left pulmonary artery, 26/16.

Following discharge from the hospital, he has been examined periodically at the cardiology clinic. His exercise tolerance remains excellent. Chest x-ray examination revealed no cardiomegaly; ECG was unchanged and echocardiogram was normal.

Cardiac Tumor Revealing in the Newborn

A Case with Spontaneous Regression

ISNARD-BALADI J; ISELIN M; VENEZIA R; POTIER JC; FOUCAULT JP
Archives des Maladies du Coeur et des Vaisseaux 78(5): May 1985; 785-789

Extracted Summary

The authors report a case of a cardiac tumour documented by 2 D echocardiography, presenting in the newborn with cardiac arrest. The echocardiographic features of multiple nodules disseminated in the ventricular walls suggested a diagnosis of rhabdomyoma. The initial course was complicated by poorly tolerated attacks of tachycardia which were rapidly brought under control with amiodarone. The long-term outcome was clinically favorable with a rapid regression of the number and size of the tumours on echocardiography, and a tendency to normalization of the electrocardiographs. The possibility of regression, which has already been reported by many investigators, suggests that these cardiac tumours may have a better prognosis than previously thought.

SELECTED CASE REPORT

The patient, Pierre-Alexandre R., was admitted to the hospital at the age of 8 days with cardiac failure. The ECG showed the sinus rhythm of 130/minute, with PR 0.12 seconds, the QRS axis strongly deviated to the left at -60°. Problems of repolarization of the ischemic type

and an important flow of injury in front and lateral and under-epicardium were observed. The chest radiography showed massive cardiomegaly with a heart to chest ratio of 0.70 and normal pulmonary vascularization. The echocardiography revealed numerous dense, homogeneous flaky

type images. Their echogenicity was higher than that of neighboring myocardium. The images remained immobile without vascularization, having close contact with the posterior and lateral walls of the left ventricle, on the right and left sides of the interventricular septum, and the major part of the ventricular cavities.

The development was characterized by the regression of the cardiac failure under treatment with digitalis and diuretics when the high frequency tachyarrhythmia appeared. The patient suffered in view of his hemodynamic condition. The situation was rapidly taken care of with amiodarone. The clinical condition of the child improved, and he was returned to the family.

At the age of 5 months the child weighed 7,200 grams, and his clinical examination was normal. The ECG was as the previous one, the heart volume regressed with the heart to chest ratio of 0.63. On the echocardiograms the echogenic masses were found in contact with the lateral wall of the left ventricle, the apex, the right and the left surfaces of the intraventricular septum, which had decreased in size and number. The ventricular passes and auriculoventricular orifices were totally free.

At 11 months, despite the treatment with amiodarone,

the child suffered from another attack of tachycardia which was provoked by infection. By that time the child weighed 9 kilograms, and was 73 centimeters tall. The clinical examination remained normal, the ECG did not change. The echocardiogram revealed the residual echogenic mass on the right surface of the intraventricular septum. Therefore the prognosis now seemed to be associated with the rhythmical complications. The dosage of amiodarone was increased.

Tachycardia did not recur at the age of 16 months. The psychomotor and physical development was normal. The child weighed 10.5 kg and was 77 centimeters tall. The clinical examination continued to be normal. The under epicardia destruction on the ECG was substituted by discrete under epicardia ischemia. The echography revealed small echogenic masses of the wall protruding into the right ventricle; the intraauricular wall became thicker; the echogenicity increased; the pericardium was free; the ventricular contractility was normal. The treatment with amiodarone was canceled due to the dermal photosensitivity and the absence of the rhythmical complications. The results of the attempts to reveal Bourneville's disease were negative. (Noetic Sciences translation)

SUPPLEMENTAL REFERENCES NEOPLASMS OF THE HEART AND MEDIASTINUM

Spontaneous Cure of Infected Left Atrial Myxoma Following Embolization

SCHWEIGER MJ; HAFFER JG; BROWN R; GIANELLY RE
American Heart Journal 99(5): May 1980; 630-634

Cardiac Fibroma: Long-Term Survival After Excision

WILLIAMS DB; DANIELSON GK; MCGOON DC; FELDT RH; EDWARDS WD
Journal of Thoracic and Cardiovascular Surgery 84(2): Aug 1982; 230-236

Spontaneous Disappearance of a Right Atrial Mass

PROCTOR CE; BROWN EJ JR; LAWSON WE; BIANCANIELLO TM; COHN PF
Journal of Ultrasound in Medicine 2: Dec 1983; 565-567

Spontaneous Regression of Cardiac Rhabdomyoma in Tuberous Sclerosis

ALKALAY AL; FERRY DA; LIN B; FINK BW; POMERANCE JJ
Clinical Pediatrics 26(10): Oct 1987; 532-535

Resolution of Intracardiac Masses [letter]

WARREN RJ; LIESCHKE GJ; HUNT D
Journal of Thoracic and Cardiovascular Surgery 97(4): Apr 1989; 637-639

Spontaneous Regression of a Heart Rhabdomyoma in Tuberous Sclerosis. Apropos of a Case (Regresion espontanea de un rabdomioma cardiaco en la esclerosis tuberosa. A proposito de un caso)

MIRO GUITART C; PERICH MR; MIRO RELAT MR; MARTIN SANTANA J; PINEDA V; ESCOFET C; MIRO BEDOS X
Revista Espanola de Cardiologia 42: Dec 1989; 697-700

Disappearance of a Cardiac Rhabdomyoma Complicating Congenital Mitral Regurgitation as Observed by Serial Two-Dimensional Echocardiography

MATSUOKA Y; NAKATI T; KAWAGUCHI K; HAYAKAWA K
Pediatric Cardiology 11(2): Apr 1990; 98-101

