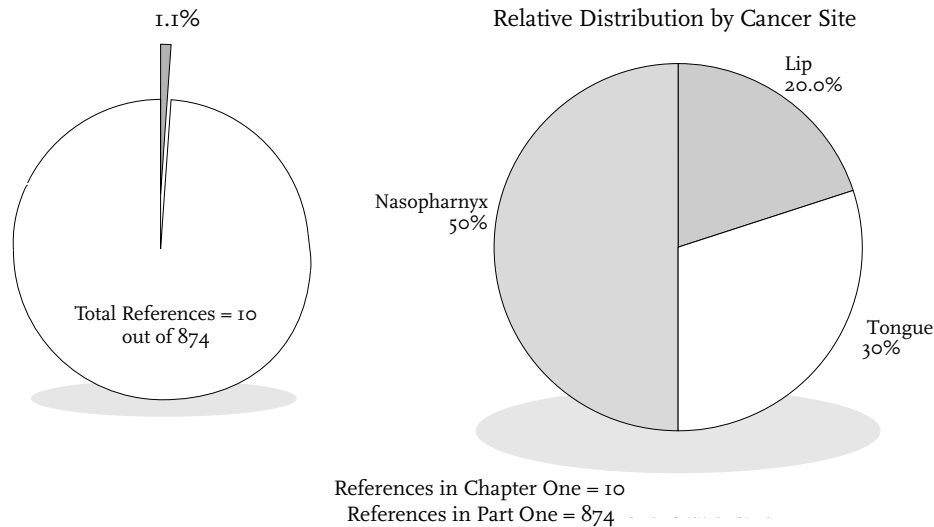


# I. Remission of Neoplasms of Lip, Oral Cavity, and Pharynx



# Remission of Neoplasms of Lip, Oral Cavity, and Pharynx



Cancers of the lip, oral cavity and pharynx account for 3.1% of the cases of cancer reported by participating tumor registries to the SEER (Surveillance, Epidemiology, and End Results) Program between 1983 and 1987. Incidence data show that cancer of the lip comprises 0.4%; tongue, 0.6%; salivary glands, floor of the mouth, gums and other parts of the mouth, 1.1%; tonsil, 0.3%; nasopharynx, 0.2%; and other parts of the buccal cavity and pharynx, 0.5% of the cancers reported during those years. Five-year survival data from the same report show a 90% survival rate for cancers of the lip; 45% for cancers of the tongue; 68% for salivary gland cancers; 52.9% for cancers of the floor of the mouth; 53.6% for cancers of the gums and other parts of the mouth; 37.8% for cancer of the tonsils; and 46.8% for nasopharyngeal cancers. Mortality data show that cancers of the oral cavity and pharynx account for 2% of the mortality cases reported to the SEER program between 1983 and 1987 (Cancer Statistics Review 1973-1987, published by the National Cancer Institute).

Of the 10 references in Chapter 1, 6 are annotated with summaries. Some annotated references also contain

1 or more case reports. Four supplementary references are included as additional research materials. Full text of 4 case reports is presented.

A summary of the chapter contents is presented in Table One and a comparative analysis of cases reported in previous reviews is presented in Table Two.

Table One: References and Case Reports in Chapter One†

Tumor Site	References (number)	Cases (number)	Cases (%)
Lip	2	0	0.0%
Tongue	3	2	0.8%
Nasopharynx	5	2	0.8%
Totals	10	4	1.6%

† Total number of case reports in Part One is 258.

Table Two: Comparison Between Other Major Literature Reviews of Cases of Spontaneous Regression of Neoplasms of the Lip, Oral Cavity and Pharynx

Tumor Site	Rohdenburg (1918) (N=185)	Fauvet (1960) (N=192)	Boyd (1966) (N=97)	Everson (1966) (N=182)	Challis (1990) (N=505)
Lip & Tongue	9	5	1	1	4
Nasopharynx	0	0	0	0	5
Totals	9	5	1	1	9

# Neoplasms of Lip, Oral Cavity and Pharynx

## Spontaneous Cure of Cancer

GODFREY F

*British Medical Journal* 2(2): Dec 31 1910; 2027

### *Extracted Summary*

A case of spontaneous cure of epithelial cancer of the left tonsil, root of the tongue, and left lateral wall of the pharynx is reported in which no treatment except antiseptic gargles and sprays were used.

### SELECTED CASE REPORT

Some years ago a man of 54 was brought to me by a colleague in the country with what I took to be carcinoma of the left tonsil, root of tongue, and left lateral wall of the pharynx. He had suffered severe pain in the throat, he was emaciated and cachectic, there was foul discharge from an extensively ulcerated surface of the irregular hard growth, and there were enlarged glands in the neck on the affected side. As surgical treatment appeared to be out of the question, I told him that nothing could be done except treatment to relieve his suffering, and that he could not live many months.

He was taken to London and seen by four surgeons of St. Bartholomew's staff, who concurred in the diagno-

sis and prognosis; and also by two surgeons on the staff of the Cancer Hospital, with the same result. A portion of the growth, removed for examination, proved it to be epithelial cancer. About eighteen months later the patient came to see me. I did not recognize him, and was thunderstruck when he told me who he was, as I had thought of him as dead. He was in perfect health, and the only trace of the growth was some smooth scar tissue. He told me that shortly after returning home and settling his affairs the pain and discharge ceased, and the growth began to disappear. He had had no treatment except antiseptic gargles and sprays, and anodynes to relieve pain.

## Spontaneous Regression of Cancer

ROXBURGH D

*British Medical Journal* 1: Jan 5 1935; 39

### *Extracted Summary*

A case of carcinoma of the tongue is reported which spontaneously disappeared. No treatment other than mouthwash was given.

### SELECTED CASE REPORT

Mrs. T., between 60 and 70 years of age, complained to me of her tongue. There was a large ulcer on the tongue opposite a jagged tooth; the glands in the neck on both sides were much enlarged. I thought it was cancer. I sent the case to Mr. Owen, surgeon at St. Mary's Hospital. He had no doubt it was cancer. He extracted the tooth. She would not consent to any further

operation and he did not urge it. He sent a small section to the pathologist of St. Mary's, who reported that it was cancer. We thought the case was hopeless. At her request I gave her a mouthwash, a weak solution of permanganate of potash. In a short time the ulcer healed, the glands of the neck disappeared, and she died seven years later of acute pneumonia.

# Psychosomatic Consideration on Cancer Patients Who Have Made A Narrow Escape from Death

IKEMI Y; NAKAGAWA S; NAKAGAWA T; MINEYASU S

*Dynamische Psychiatrie* 31: 1975; 77-92

## *Extracted Summary*

Clinical histories of five cases of spontaneous regression of cancer (SRC) have been analyzed from the psychosomatic point of view. As a result, some common features have been observed in their psychophysiological conditions. In all five cases, the absence of anxious and depressive reactions and the dramatic change of an outlook on life seemed to have led to the full activation of their innate self-recuperative potentials and to have helped them to make a narrow escape from death. Such an extraordinary psychological achievement was supported and encouraged by their religious faith or favorable change of human environment. Furthermore, the authors feel that the background of Oriental thought also might help them reach such a blessed state of mind. As one of somatic conditions which might contribute to SRC in them, the unchanged or rather elevated immunological capacity which was usually lowered in cancer patients has been confirmed in three of them.

The following criteria were used by the authors to determine a diagnosis of spontaneous regression of cancer: 1. The reduction or disappearance of a pathohistologically confirmed tumor in the absence of any active anti-cancer therapy; 2. The long survival of the host body due to extremely delayed progress or prolonged arrest of cancer with no rapid growth or metastases of a malignant tumor; 3. The long survival of the host body with no cachectic change of cancer in the presence of some anti-cancer therapy, or the death of the host body after long survival due to some cause other than cancer. The authors note that SRC is not equated with spontaneous cure.

## SELECTED CASE REPORT

**C**ase 1: Y. H., a male church worker, died in November 1964, at the age of seventy-five. Clinical History: The patient was 64 years old when he noted sudden nasal bleeding and nasal obstruction while at work in March 1950. Dr. F, an otorhinolaryngologist, after having examined the patient, suspected malignant cancer and sent him to the department of otorhinolaryngology of the Kyushu University Hospital. An exploratory excision was conducted from a polyp on the right maxilla. Through the histological examination, a diagnosis of "cancer of the upper jaw (right side)" was made. The resection of the tumor was conducted on April 14, 1950.

He complained of hoarseness in January 1951 when he thought he had caught a cold. At first he was treated under the diagnosis of chronic laryngitis, but the hoarseness was aggravated. Because of increased dry feeling in the laryngeal region as well as of hoarseness, the patient was examined again at the university hospital (age 66). A new growth of a tumor was discovered in the left side of the vocal cord. A record of this has been preserved on the chart at the university hospital. An exploratory excision followed by the microscopic histological examination revealed cancrroid (squamonocell carcinoma).

Prof. S. of the department of otorhinolaryngology recommended that the patient be operated upon, but the patient declined it. He lived for the next thirteen years without receiving any regular treatment including radiotherapy, anti-cancer drug therapy, to say nothing of an

operation. He died at the age of 78 when he received a bruise on the back which eventually caused his general deterioration.

Life History: The patient was born on a farm in 1886. At the age of eighteen, he became a member of a religious organization (Shinto sect). He was appointed teacher of a church when he was twenty-one. He then became a district leader of the organization and devoted himself to church work throughout his life.

He was a taciturn and self-punitive person by nature. After the end of Second World War, his religious organization was exposed to a great crisis. During the war he was asked to take over important business in the administration of his town. With the end of the war, he had a very difficult time carrying out his responsibilities for his neighbors as well as for his church work. Under these circumstances, he suffered from maxilla cancer in 1950.

In regard to the state of mind when he declined the laryngoresection as mentioned above, he said he was ready to accept the situation as it was on the basis of his religious conviction. He preferred continuing to be a preacher as long as he could speak to losing his voice by the operation. He felt "This is God's will and I have no complaint about it. Whatever should happen will just happen."

Course of Illness: Ten days after "the sentence of cancer," he visited the president of the religious organization, who said to him: "Remember that you are an

invaluable asset for our church." This made him feel very happy and he shed tears of joy all the way back home. Since this moving experience, his hoarseness began to improve and he began to give a short speech at his church four months later (July 1952). At this time his voice was still hoarse. Six months later, however, he spoke thirty minutes in the church and this time his voice was quite clear (this sermon was tape recorded).

In the literature concerning psychosomatic aspects of

cancer, it has been noted that cancer patients, after having become aware of their cancer, often show a tendency of repression and are apt to lapse into depression with lack of motivation toward life and fear of death. This patient, however, did not demonstrate these characteristics at all. Today Dr. F. says: "The cancer of this patient seemed to be practically cured. When I looked into the vocal cord through laryngoscopy, the tumor was gone..."

## Spontaneous Cure of Adenoid Cystic Carcinoma

### *Meeting Abstract*

CONLEY JJ; SACHS ME

*Otolaryngology-Head and Neck Surgery* 89(5,section2): 1981; 149

#### *Extracted Summary*

Absence of discernible disease for an acceptable interval of time supports the supposition that the disease may have been cured. The most striking type of spontaneous cure of any tumor is the spontaneous regression of a gross neoplasm that is measurable and obvious without treatment of any type. This has never been reported for adenoid cystic carcinoma, and indeed it is a rare biologic phenomenon with any neoplasm. The evidence in this report is presented and the evidence is circumstantial. Its premise is that the operated-on adenoid cystic carcinoma in these specific circumstances had overwhelming possibilities to recur, but failed to do so. This suggests that the presumed microscopic residual cancer was cured by a biologic process originating in the host or in the neoplasm itself. Three long-term cases, two of pulmonary metastasis, are presented to support this possibility.

## Spontaneous Regression of Lung Metastases of Adenoid Cystic Carcinoma

GRILLET B; DEMEDTS M; ROELENS J; GODDEERIS P; FOSSION E

*Chest* 85(2): Feb 1984; 289-291

#### *Extracted Summary*

Two patients with spontaneous regression of histologically confirmed lung metastases from a classic cribriform adenoid cystic carcinoma are presented. The first case was moribund when multiple small lung metastases were detected, but after a very strict diet, he presented progressive improvement in his general condition and regression of the metastases. In the second case, three large lung metastases and a subcutaneous metastasis regressed after several local recurrences of the primary tumor had been removed.

#### SELECTED CASE REPORT

**I**n 1959, a 26-year-old man complained of a painful tumor, 1 centimeter in diameter, located in the left parotid gland. The lesion was locally resected and the microscopic analysis revealed a classic adenoid cystic carcinoma: the tumor cells were arranged in anastomosing cords and clumps, embedded in a hyaline stroma. The latter was extensive in multiple areas, with cribriform arrangement and compression with breaking up of the epithelial component.

Because of a recurrence, the full parotid gland was removed in 1962, followed by radiotherapy. Other recurrences were treated with local resection and radiotherapy in 1967, and with local implantation of radioactive gold in 1969.

In 1969, a chest roentgenogram showed multiple opacities mainly in the right lower lung field and in the left middle field. The patient's general condition by then was very poor (general exhaustion and loss of 8 kilograms

of weight within 3 months). The patient started a diet free of fruit, potatoes, sugar, animal proteins and animal fats. Within a few months, his condition gradually improved.

In 1972, open lung biopsy confirmed the diagnosis of metastases of adenoid cystic carcinoma. The lung

lesions did not change until 1975, when regression clearly started. Since 1980, lesions are only barely visible.

Because of ulceration in the left parotid area, the seven implanted gold particles were removed in 1982. Biopsy showed lesions of irradiation without remaining tumor. Since then, the patient remained in good health.

## Involution of Juvenile Nasopharyngeal Angiofibroma with Intracranial Extension

### *A Case Report with Computed Tomographic Assessment*

JACOBSSON M; PETRUSON B; RUTH M; SVENDSEN P

*Archives of Otolaryngology* 115(2): Feb 1989; p238-9

#### *Extracted Summary*

In September 1979 the patient, a man born in 1964, noticed pain and swelling of the right cheek in combination with periods of epistaxis. A computed tomographic scan revealed a tumor extending from the middle of the right nasal cavity into the right maxillary antrum and up toward the orbital floor with destruction of the medial and lateral walls of the antrum and continuing into the sphenoid sinus on the right side and dorsal to the pterygoid process up under the base of the skull. Angiography showed arterial supply mainly from the right external carotid artery, but also from the right internal carotid artery and the left external carotid artery. The process was diagnosed as a juvenile nasopharyngeal angiofibroma. In spite of two attempts at resection of the tumor and arterial embolization, the tumor progressed intracranially. Further operative attempts were decided against, and the patient was followed with repeated computed tomographic scans. The tumor eventually became involuted; eight years after the initial diagnosis, there was no evidence by computed tomographic scans of intracranial growth of the tumor.

#### SUPPLEMENTAL REFERENCES

##### NEOPLASMS OF LIP, ORAL CAVITY AND PHARYNX

A Sore Diagnosed as Cancer of the Lip in Early Life:  
Recovery Without Operation

CROSBIE RP

*British Medical Journal* 1: Feb 11 1899

II. Spontaneous Disappearance of Carcinoma of the  
Lip

FREEMAN L

*Journal of the American Medical Association* 36: May 11  
1901; 1309

Cancer of Tongue: Excision of Tongue: Cancer of  
Stomach 34 Years Later

MANSON JS

*British Medical Journal* 1: June 24 1922; 996

Complete Regression of Two Non-operated  
Hypopharyngeal Carcinomas

TEMESREKASI D

*Archiv für Klinische und Experimentelle Ohren-, Nasen-  
und Kehlkopfsheilkunde* 194: 1969; 323-328